

TECHNICAL BULLETIN



Feline Osteoarthritis, a Common and Painful Disease: Diagnosis, Treatment, New Resources and Future Options



THE NEW SCIENCE OF FELINE OA PAIN

Sorrel Langley-Hobbs MA BVetMed DSAS(O) DipECVS FHEA MRCVS
Chair in Small Animal Orthopaedic Surgery
Director of the Masters in Veterinary Science programme
RCVS Specialist in Small Animal Surgery (Orthopaedics)
EBVS European Specialist in Small Animal Surgery
Bristol Vet School, University of Bristol


Dr Edwina Gildea MVB MRCVS
Zoetis UK Companion Animal Veterinary Lead

INTRODUCTION

Osteoarthritis (OA) in the cat is a very common condition with 40% of all cats having clinical signs and >90% of cats older than 12 showing radiographic evidence of OA.^{1,2} The condition is not exclusive to older cats and clinical studies have shown that even cats as young as 2 years old can suffer from OA. However, as a disease the clinical signs are infrequently recognised by pet owners and the condition is underdiagnosed by the veterinary profession, with only 13% of affected cats globally being diagnosed.² As veterinarians, we understand that assessing cats for its presence and educating owners to recognise the signs is critical (**Table 1**). Starting to screen cats as early as 7-10 years of age will help to establish a baseline of 'normal' for that cat and may uncover OA early in the disease. Active screening and early identification can increase the number of cats treated and improve the quality of life of cats suffering from the pain and reduced mobility associated with OA.

PREVALENCE

40%
OF ALL CATS
show clinical signs
of osteoarthritis





Feline Osteoarthritis, a Common and Painful Disease: Diagnosis, Treatment, New Resources and Future Options

WHAT IS OSTEOARTHRITIS (OA)?

Degenerative joint disease refers to damage in both the appendicular and axial skeletal systems, with most of the cases diagnosed as osteoarthritis. Osteoarthritis implies a joint problem, primarily associated with degeneration and loss of cartilage and proliferation of bone in the form of osteophytes around the joint. This results in a joint that has a reduced range of motion and one that is undergoing low grade inflammation resulting in varying degrees of pain and swelling of the offending joint(s). It is common in cats that multiple joints are affected.

In cats, osteoarthritis usually occurs as a primary problem with no easily identifiable underlying cause, but it can also occur secondary to underlying developmental joint disease such as hip dysplasia (**Figure 1**) or subsequent to a joint injury such as

an intra-articular fracture or luxation. Cats develop osteoarthritis in all their large joints, but particularly the hip, hock and elbow joint (**Figure 2**).^{3,4} Over 80% of cats greater than 12 years of age had axial skeletal changes.⁴ Appendicular skeletal changes are even more common with over 90% of cats of all ages having radiographic changes in at least 1 joint.³

Veterinarians globally report that decreased agility and reduced mobility are the most common signs reported to them for cats diagnosed with OA (**Table 1**). Behavioural changes are also common and usually associated with the cats' decreased agility and reluctance to move around.^{5,6} Cats presenting with behavioural problems can be easy to miss and is another reason to screen all cats for OA around 7-10 years of age. These findings are in line with published studies on feline OA.

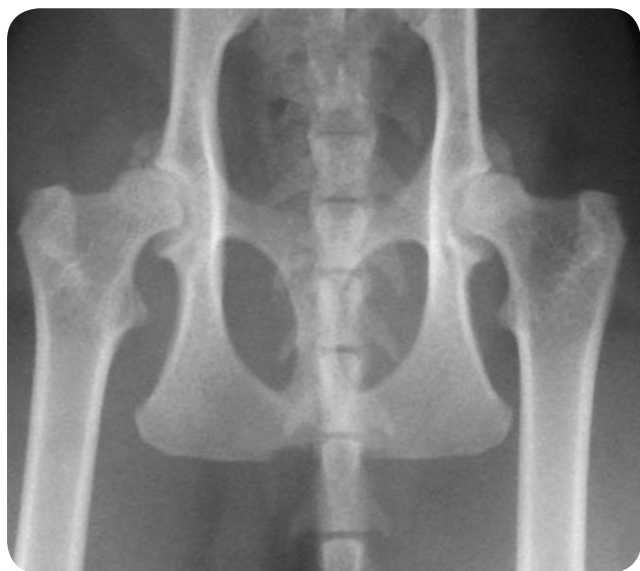

Figure 1. Hip osteoarthritis in an eight-year-old domestic short-haired cat secondary to hip dysplasia. Large bilateral osteophytes are present on the cranial acetabulum.

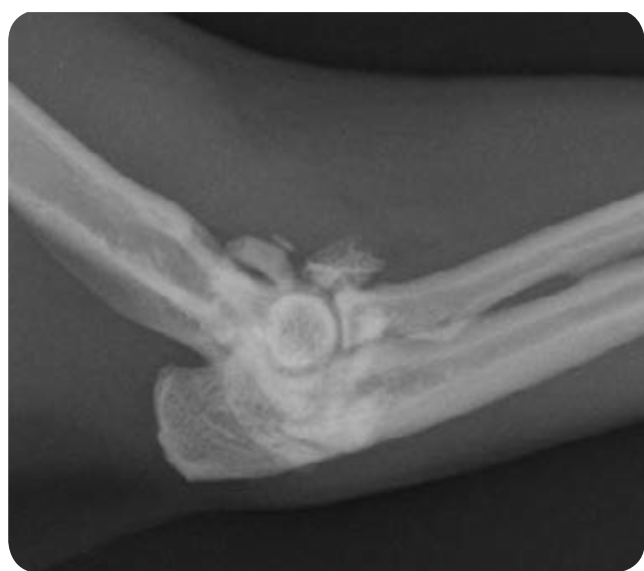

Figure 2. Elbow osteoarthritis in an eleven-year-old Burmese cat. There are periarticular osteophytes and joint mice. Bilateral elbow changes were present.



Feline Osteoarthritis, a Common and Painful Disease: Diagnosis, Treatment, New Resources and Future Options



Table 1a. Clinical signs reported by cat owners to the veterinarian²

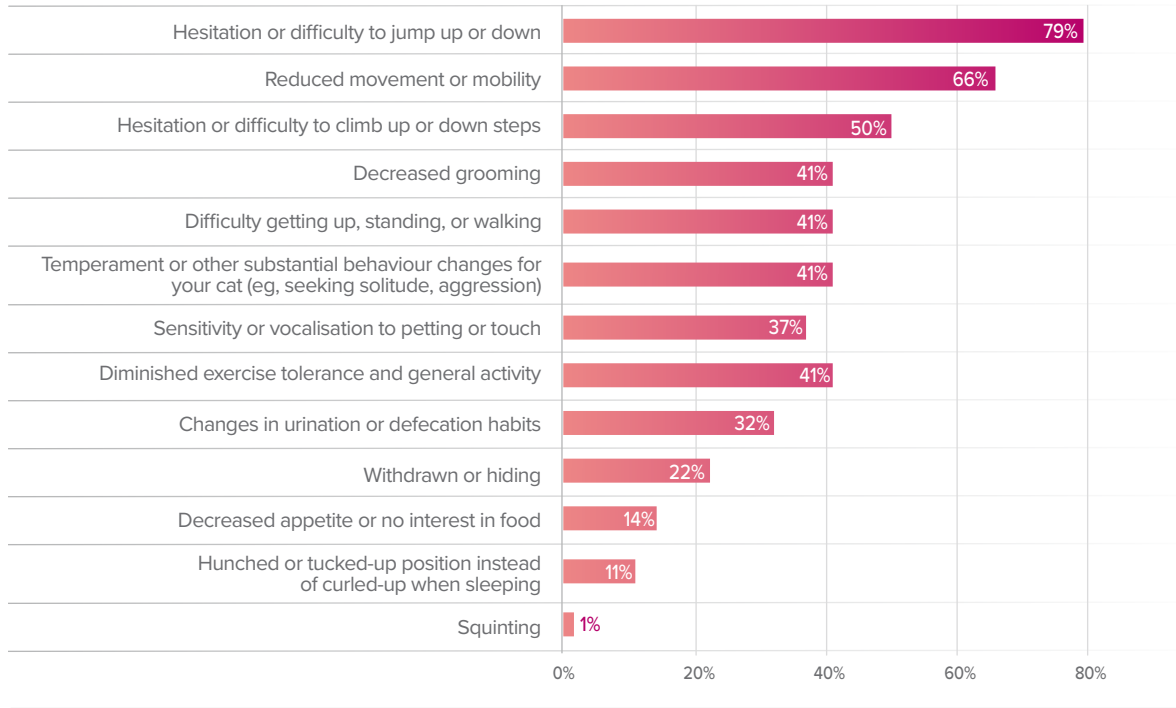
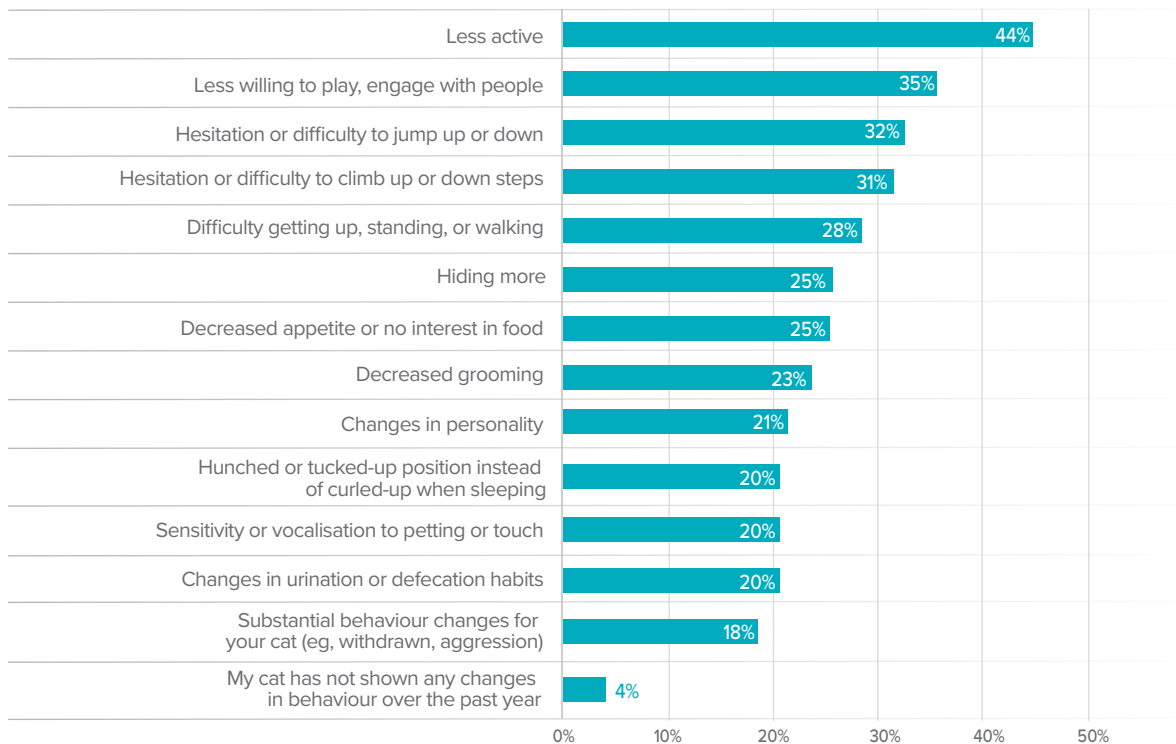


Table 1b. Pet Owner Most common behaviour changes seen in their arthritic cats²



Feline Osteoarthritis, a Common and Painful Disease: Diagnosis, Treatment, New Resources and Future Options



HOW TO DIAGNOSE OA

Owners may believe that it is normal for their older cat to sleep more and be less active or may only notice more severe signs of OA pain. As veterinarians we need to be aware of the high incidence of OA in cats and not dismiss an owner's observation that their cat cannot jump as high anymore as being normal for an older cat. If the cat is in pain and unwilling to move around because of osteoarthritis, then it is important to educate owners to this possibility and to try to intervene to alleviate some of the pain that the cat is experiencing. The good news is, cat owners are interested in learning more about OA in cats. In a global survey, when educated on OA as an extremely common, painful disease that could be treated, 53% cat owners found the information relevant to their cat, and 39% were motivated to make an appointment with their veterinarian.²

WHEN PET OWNERS ARE
EDUCATED ON OA,

39%

WERE MOTIVATED TO MAKE
AN APPOINTMENT WITH
THEIR VETERINARIAN.



UNTREATED PAIN HAS DETRIMENTAL IMPACT...

- Musculoskeletal deterioration vis-a-vis reduced mobility/activity
- Cognitive and affective decline
- Impacts human animal bond
- Untreated pain becomes harder to manage (central sensitisation)
- Untreated pain can impact a cat's quality of life⁷



THE NEW SCIENCE OF
FELINE OA PAIN

Feline Osteoarthritis, a Common and Painful Disease: Diagnosis, Treatment, New Resources and Future Options



There are some useful questions that a veterinarian can ask of an owner to identify cats with musculoskeletal problems (Table 2). Alternatively, the cat owner can be asked to complete a validated questionnaire prior to the consultation and then regularly thereafter to assess response to treatment.^{8,9} *Engage the owner and assist your diagnosis by asking them to record their cat in their natural environment without the stress of being at the clinic.*

CHECK LISTS CAN HELP TO IDENTIFY SIGNS OF OSTEOARTHRITIS IN CATS.

Table 2.

QUESTIONS TO ASK OWNERS OF CATS WITH THE POSSIBILITY OF OSTEOARTHRITIS.¹⁰

HAVE ANY OF THE FOLLOWING CHANGES IN YOUR CAT'S ABILITY OR ENTHUSIASM BEEN NOTICED?

- Go up and/or down stairs
- Use the cat flap/door
- Jump onto or off the bed/sofa/your lap/work surfaces, etc.
- Jump or climb into/onto its favourite bed
- Play
- Climb trees/fences, etc.
- Use scratching posts (or other substrates)

HAVE ANY OF THE FOLLOWING BEEN NOTICED?

- A stiff or stilted gait (ie, less fluid—less 'feline'—motion)
- A limp
- Vocalising or hissing in response to moving around or being stroked over joints

HAVE ANY OF THE FOLLOWING CHANGES IN YOUR CAT'S BEHAVIOUR BEEN DETECTED?

- Grumpy or less happy with people and other animals in the house
- More withdrawn – interacting less with others in the house
- Less active
- Sleeping in different locations eg, on the floor
- Not coming upstairs/into the house any more
- Passing urine or faeces in abnormal locations eg, beside the litter tray, other locations inside the house
- Purring less
- A reduced appetite
- Changes in coat condition (eg, matted, scruffy) and/or grooming behaviour—eg, grooming less overall, neglecting certain areas (pain over joints or pain turning to groom certain areas), overgrooming certain areas (eg, due to pain over a joint)

OTHER MISCELLANEOUS QUESTIONS

- Have there been any changes in weight?
- Has the cat had any known trauma or musculoskeletal injuries in the past?
- Is there any knowledge concerning affected relatives? (eg, hip dysplasia is more common in certain breeds eg, Maine Coon)



Feline Osteoarthritis, a Common and Painful Disease: Diagnosis, Treatment, New Resources and Future Options



ORTHOPAEDIC EXAMINATION


Performing an orthopaedic examination of a cat can be tricky and often requires patience.

There are **'feline friendly' approaches to handling a cat** [▶](#) that can be implemented in the practice.^{11,12}


In a cat that is impossible to examine, owner videos in the home environment that show their concerns are needed. Ask them to video the cat doing the things it finds difficult – eg, jumping or climbing stairs. In the more amenable cat, watching it walk around the consulting room and allowing or encouraging it to jump on and off a chair can be helpful to observe if there are any gait abnormalities. Following the visual observation, an examination of the joints is recommended. This is best carried out with an assistant holding the cat gently over its chest. The changes to look for in individual joints are swelling or enlargement, crepitus, decreased range of motion, and pain. However, bear in mind that not all joints will be painful and not all painful joints will have osteoarthritis. The presence of crepitus, joint thickening, and joint effusion has been shown to be predictive of the presence of radiographic DJD.³

DR DUNCAN LASCELLES DEMONSTRATES A FELINE-FRIENDLY APPROACH TO AN OA EXAM IN A SERIES OF SHORT VIDEOS

Successful OA Exams in Cats



THE NEW SCIENCE OF
FELINE OA PAIN



- [▶ Keys to a Successful OA Exam of Cats](#)
- [▶ Assessment of the Cat Prior to Joint Examination](#)
- [▶ Approach to Starting the Evaluations of Joints](#)
- [▶ Lateral Recumbency: The Hip Joint](#)
- [▶ Lateral Recumbency: The Stifle Joint](#)
- [▶ Lateral Recumbency: The Elbow Joint](#)
- [▶ Lateral Recumbency: The Shoulder Joint](#)
- [▶ Lateral Recumbency: The Lumbosacral Space](#)
- [▶ Standing Position: The Forelimb Joints](#)
- [▶ Standing Position: The Hindlimb Joints](#)
- [▶ Standing Position: The Lumbosacral Space](#)



THE NEW SCIENCE OF
FELINE OA PAIN

Feline Osteoarthritis, a Common and Painful Disease: Diagnosis, Treatment, New Resources and Future Options



CONFIRMING THE DIAGNOSIS

Although the combination of appropriate clinical signs and physical examination findings may lead you to be fairly certain a cat has OA, it is ideal to try to confirm your suspicions by seeing radiographic changes. The primary radiographic change associated with osteoarthritis is the presence of periarticular osteophyte formation, although this is not always present or easily identifiable in every case. It is important to appreciate that osteoarthritis may be present in the absence of obvious radiographic changes. Contrarily, the presence of radiographic changes does not always correlate with clinical signs of osteoarthritis nor the degree of pain suffered. Occasionally, cats develop excessive periarticular mineralisation and ossified bodies adjacent to their joints, particularly in the stifle joint (**Figure 3**).

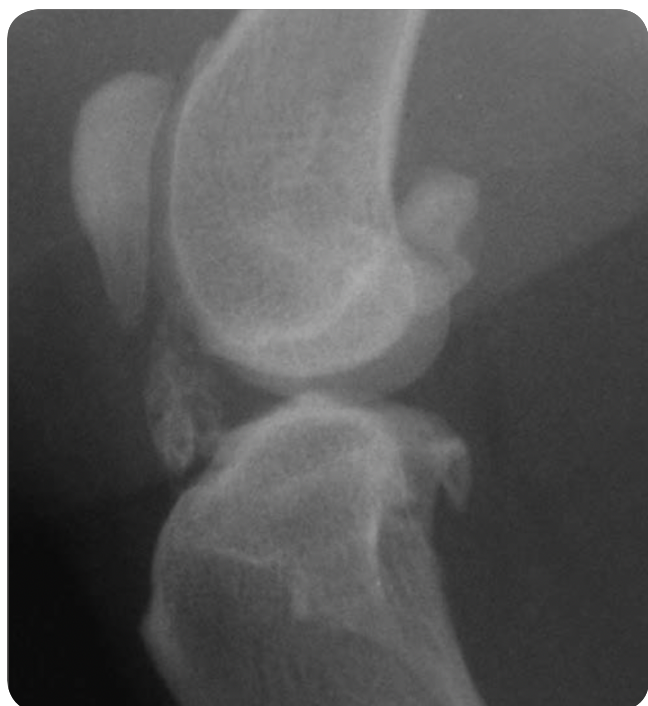


Figure 3. Mineralisation of the intra-articular structures in the stifle of a seven-year-old male neutered cat. There is also mild periarticular osteophytosis of the stifle with new bone on the proximal pole of the patella and trochlear ridge.

TREATMENT

Once you have established that a cat does have osteoarthritis, a treatment plan needs to be formulated. The aims for treatment are to treat the primary problem (pain), maintain mobility, and limit progression of the disease. A multimodal approach to management should be considered while also factoring in the burden of care and the relative impact on owner compliance.



Feline Osteoarthritis, a Common and Painful Disease: Diagnosis, Treatment, New Resources and Future Options



PAIN MANAGEMENT THERAPY

Pain management therapy is the pivotal point around which all other supportive management is implemented. For this reason, it is essential to not only diagnose the condition but also to treat the associated pain with clinically effective medication. In comparison to dogs, there are limited drug therapies licensed for use in cats. Furthermore, not all therapies are licensed in all countries. As such, many medications used by veterinarians today do not have safety and/or efficacy data to support their use in the cat. Non-steroidal anti-inflammatory drugs (NSAIDs) are the main treatment modality in most species, and the cat is no different. Although robenocoxib and meloxicam are the only NSAIDs licensed for long-term use in the cat, they are not licensed in every country.

Multimodal analgesic therapy can be applied, but consideration needs to be taken to recognise what is licensed as well as what is feasible for the owner to implement for a condition that requires long-term management on a daily basis. Oral delivery of medication may be difficult for pet owners whether liquid or tablet/pill. In fact, difficult treatment paradigms may disrupt the human-animal bond. Evidence-based medicine suggests veterinarians should choose a pain medication with high-level evidence to support use, ideally with efficacy and safety proven in the cat in multicentre controlled trials. Pain medication that is easy to deliver is another important consideration for selecting a pain management treatment for cats with OA.

A COMPREHENSIVE MANAGEMENT PROGRAM INCLUDES:

- Pain Management Therapy
- Dietary modulation
- Weight loss if required
- Physical therapy
- Exercise
- Environmental modification
- Surgery

NSAIDS, OLDER CATS, AND RENAL DISEASE?

Older cats with OA may have concurrent disease that may be of concern to veterinarians when considering administering drug therapy, particularly as it may need to be given long term. Routine blood and urine analysis is recommended prior to starting NSAID therapy to investigate for renal or hepatic problems. It is also advisable to measure blood pressure as inhibition of cyclooxygenase (COX) in the kidneys can exacerbate preexisting hypertension. If cats are diagnosed with chronic kidney disease (CKD), then NSAIDs can still be used with appropriate checks and follow ups.¹³



Feline Osteoarthritis, a Common and Painful Disease: Diagnosis, Treatment, New Resources and Future Options



NUTRACEUTICALS AND DIETS

Nutraceuticals are food supplements with potential health benefits. The claims for these products include anti-inflammatory properties, cartilage regeneration, and delayed cartilage degeneration, with the potential to improve mobility and decrease stiffness in animals. However, there is currently no definitive, unbiased *in vivo* measurable evidence that they work, and there is little evidence available for evaluating long-term impact. Diets rich in omega-3 fatty acids are recommended for cats with DJD.¹⁴ Studies have provided evidence that n-3 fatty acid supplementation can reduce the inflammatory and matrix degradative response elicited by chondrocytes during OA progression.¹⁵ These diets may also assist with weight loss.

WEIGHT REDUCTION IF NEEDED

While obesity has not been proven as a risk factor for OA in cats, it is notable that approximately 14% of older cats suffering from OA are obese.¹⁶ Adipose tissue secretes a mixture of cytokines that circulate throughout the body, contributing to the pathology of many diseases, including DJD, and to the hypersensitisation process in general. Either maintaining or regaining a lean body condition score is central to the treatment of chronic pain.¹⁷ Weight loss in overweight or obese cats with OA should be attempted by the use of low-calorie diets and encouraging exercise. The latter might be improved by environmental modification. Regular monitoring by revisits, including weight measurement, are recommended to maintain motivation.

EXERCISE

Encouraging the cat to move around more can be achieved by the use of toys, feeding puzzles, playing chase games, and catnip toys. A cat tower/scratcher with different levels that are easily accessible may encourage more activity. Owners should try to interact with their cats and encourage play several times daily. Establishing a baseline of 'normal' for each cat also acts as a reminder to the cat owner of what their cat used to enjoy doing, so they can find ways to continue to provide that as part of their cat's OA therapy.



ENVIRONMENTAL MODIFICATION

Altering the cats' environment to accommodate the disability associated with osteoarthritis can have beneficial effects. Cats are creatures of routine and masters of their territory; cat owners can help to restore the routines disrupted by OA pain. Modifications to the environment can be achieved by ensuring the cat has easy access to its food and water bowls, sleeping area, and litter tray. If this is not the case, cat owners can provide access by means of steps or a ramp. A litter tray with a low side can aid entry and prevent accidents in the house. In houses with multiple floors, consider multiple litter trays so the cat does not have to tackle the stairs to get to the litter tray. Ensure the cat flap/door is easily accessible both from inside and outside. These slight modifications may lead to less effort on the cat's part to perform activities of daily living and improve their life quality overall.



Feline Osteoarthritis, a Common and Painful Disease: Diagnosis, Treatment, New Resources and Future Options



FELINE PHYSICAL THERAPY

Physiotherapy and hydrotherapy will not suit every cat, but with an amenable animal these therapies can have advantageous effects. Where possible, a programme should be designed, implemented, and monitored by a qualified veterinary practitioner. Range of motion exercises and massage can be performed in home and be useful at reducing muscle pain.¹⁴ Cold and heat therapy, laser, ultrasound, and shock wave are other therapies that could be considered, although there are few studies published about their usage in cats. Acupuncture can be beneficial and has been used in cats with arthritis. It may take several sessions before an improvement is seen and then intermittent top-up treatments can be used for maintenance. Acupuncture can be used in combination with analgesic drugs.

SURGERY

There may be an underlying condition that is causing or predisposing a cat to osteoarthritis, such as cranial cruciate ligament rupture, elbow dysplasia, patellar luxation, hip dysplasia, and traumatic injury. Underlying problems with the joint lead to degeneration and inflammation causing synovitis, loss of cartilage, and sclerosis of the subchondral bone. Elimination of these underlying problems can be an important part of managing or preventing and limiting osteoarthritis formation. Surgical correction of joint stability, removal of osteochondral fragments, and correction of inappropriate loading of the joint is often needed to slow the progression of osteoarthritis and give the best outcome. Salvage surgery by joint fusion, replacement, or excision can all be performed in the end-stage joint where medical management and environmental modification are no longer deemed effective.

WHAT DOES THE FUTURE HOLD FOR CATS WITH OSTEOARTHRITIS?

As previously discussed, the multimodal management of OA relies on effective analgesia. Although current analgesic options are effective, current therapeutics may be difficult for pet owners to administer and there remains some limitation around the availability of licensed medications in different countries. Safety considerations may limit long-term use or use in the face of concurrent disease (eg, CKD).

A new analgesic approach shows potential—a therapeutic antibody that targets a novel driver in the pain pathway—Nerve Growth Factor (NGF).

Research into Nerve Growth Factor (NGF) and its interaction with tropomyosin receptor kinase A (TrkA) has led to some interesting findings that could move pain management into a new era for cats. It is interesting to note that this is a different mechanism than the more commonly known prostaglandin pathway targeted by NSAIDs, including EP4, 'piprant' NSAIDs. This is the first novel OA pain pathway showing promise for new therapeutics in several decades.


A new analgesic approach shows potential—a therapeutic antibody that targets a novel driver in the pain pathway—Nerve Growth Factor (NGF).

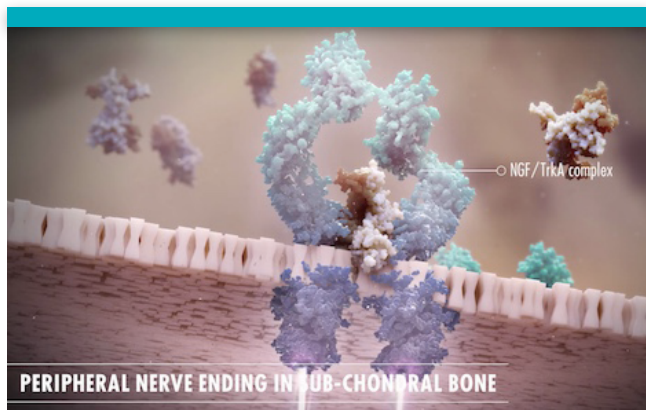



Feline Osteoarthritis, a Common and Painful Disease: Diagnosis, Treatment, New Resources and Future Options

NERVE GROWTH FACTOR— A KEY DRIVER IN THE PAIN PATHWAY

Studies have identified a new key player in the transmission of pain associated with osteoarthritis (OA) in people, dogs and cats.¹⁸ In adults, Nerve Growth Factor (NGF) plays a significant role in pain signalling. A 3-minute **VIDEO**  is available on the mechanism of action of Nerve Growth Factor in OA pain. NGF is an integral component of central sensitisation (wind up), spinal cord plasticity, and maladaptive pain signalling, which inevitably results in hyperalgesia (wind up).¹⁹ As a result of these research findings, several anti-NGF/TrkA signalling strategies have been investigated for their efficacy and safety in modifying pain. Therapeutic antibodies (also called monoclonal antibodies [mAbs]) that bind to NGF—and thereby block the pain signal—are leading the way within this new field with pilot safety and efficacy studies showing promise in cats.²⁰



NERVE GROWTH FACTOR INTERACTS WITH IMMUNE CELLS IN THE JOINT

NGF is elevated in osteoarthritic joints in the dog.²¹ Not only is it released from damaged tissues, but it is also found in some immune cells associated with proinflammatory mediators.²² The same receptor, TrkA, also appears on these cells.

THERAPEUTIC ANTIBODIES ARE FUNDAMENTALLY DIFFERENT

Therapeutic antibodies are metabolised differently than drugs and generally have different safety profiles. They are broken down within cells into amino acids and peptides and are therefore not metabolised in the liver or kidneys, converted into reactive or toxic metabolites, or excreted in urine. Thus, they are unlikely to cause drug-drug interactions or to induce liver or kidney toxicity.^{19,23}

Monoclonal antibodies are cleared via multiple potential pathways:

1. Binding to target.
2. Antidrug antibodies in circulation.
3. Flow out of capillaries into interstitial space, taken up by cells and catabolised.

Anti-NGF therapy may come to represent a new class of veterinary medications and may be an effective new way for veterinarians to provide safe, long-lasting control of chronic pain for cats.

IN SUMMARY

Feline OA is very common and there is opportunity to diagnose this painful condition in more cats. Early screening can establish a cat's baseline. Checklists can help to identify signs of osteoarthritis in cats. There are many opportunities for intervention, including analgesics, environmental adjustments, activity, and surgery as needed. There are also new antibody therapies on the horizon. With prolonged duration of activity (~1 month) and easy administration to cats with a subcutaneous injection, this new therapeutic antibody approach may be the solution that veterinarians, cat owners, and cats suffering from OA have been waiting for.





THE NEW SCIENCE OF FELINE OA PAIN

References: **1.** Cimino Brown D et al. What can we learn from osteoarthritis pain in companion animals? *Clin Exp Rheumatol.* 2017;35 suppl 107(5):53-58. **2.** KG MarketSense 2018 Global Veterinarian Market Research **3.** Lascelles BD, Dong YH, Marcellin-Little DJ, et al. Relationship of orthopedic examination, goniometric measurements, and radiographic signs of degenerative joint disease in cats. *BMC Vet Res.* 2012;8:10. **4.** Hardie EM, Roe SC, Martin FR: Radiographic evidence of degenerative joint disease in geriatric cats: 100 cases (1994-1997). *J Am Vet Med Assoc.* 2002;220(5):628-632. **5.** Merola I, Mills DS. Behavioural signs of pain in cats: an expert consensus. *PLoS One.* 2016. **6.** Bennett D, Morton C. A study of owner observed behavioural and lifestyle changes in cats with musculoskeletal disease before and after analgesic therapy. *J Feline Med Surg.* 2009;11(12):997-1004 **7.** Benito J et al. Owner-assessed indices of quality of life in cats and the relationship to the presence of degenerative joint disease. *J Feline Med Surg.* 2012;14(12): 863-870. **8.** Zamprogno H, Hansen BD, Bondell HD, et al. Item generation and design testing of a questionnaire to assess degenerative joint disease-associated pain in cats. *Am J Vet Res.* 2010;71(12):1417-1424. **9.** Benito J, Depuy V, Hardie E, et al. Reliability and discriminatory testing of a client-based metrology instrument, feline musculoskeletal pain index (FMPI) for the evaluation of degenerative joint disease-associated pain in cats. *Vet J.* 2013;196(3):368-373. **10.** Caney S. Feline Arthritis. *Feline Focus,* 2007, 17(3) 11-17. **11.** <https://catfriendlyclinic.org/vets-nurses>. **12.** <https://catvets.com/cfp/veterinary-professionals> **13.** Sparkes AH, Heiene R, Lascelles BD, et al. ISFM and AAFP consensus guidelines: long-term use of NSAIDs in cats. *J Feline Med Surg.* 2010;12(7):521-538. **14.** Lascelles BD, Robertson SA. DJD-associated pain in cats: what can we do to promote patient comfort? *J Feline Med Surg.* 2010;12(3):200-212. **15.** Goggs R, Vaughan-Thomas A, Clegg PD, et al. Nutraceutical therapies for degenerative joint diseases: a critical review. *Crit Rev Food Sci Nutr.* 2005;45(3):145-164. **16.** Bennett D et al. Osteoarthritis in the cat: how common is it and how easy to recognise. *J Feline Med Surg.* 2012;14(1): 65-75. **17.** Epstein M, Rodan I, Griffenhagen G, et al. 2015 AAHA/AAFP pain management guidelines for dogs and cats. *J Feline Med Surg.* 2015;17(3):251-272. **18.** Enomoto M, Mantyh PW, Murrell J, et al. Anti-nerve growth factor monoclonal antibodies for the control of pain in dogs and cats. *Vet Rec.* 2019;184(1):23. **19.** Epstein ME. Anti-nerve growth factor monoclonal antibody: a prospective new therapy for canine and feline osteoarthritis. *Vet Rec.* 2019;184(1):20-22. **20.** Gruen ME, Thomson AE, Griffith EH, et al. A feline-specific anti-nerve growth factor antibody improves mobility in cats with degenerative joint disease-associated pain: a pilot proof of concept study. *J Vet Intern Med.* 2016;30(4):1138-1148. **21.** Isola M et al. Nerve growth factor concentrations in the synovial fluid from healthy dogs and dogs with secondary osteoarthritis. *Vet Comp Orthop Traumatol.* 2011;24(4):279-284. **22.** Mantyh PW, Koltzenburg M, Mendell LM, Tive L, Shelton DL. Antagonism of nerve growth factor-TrkA signaling and the relief of pain. *Anesthesiology.* 2011;115(1):189-204. **23.** Olivry T, Bainbridge G. Advances in veterinary medicine: therapeutic monoclonal antibodies for companion animals. *Clinician's Brief.* <http://www.cliniciansbrief.com/article/advances-veterinary-medicine-therapeutic-monoclonal-antibodies-companion-animals>. Published March 2015.